



## Triple Pelvic Osteotomy

### Maintaining Joint Congruency for Young Dogs

Triple pelvic osteotomy (TPO) is a surgery that preserves the natural hip joint, eliminates subluxation (laxity), and prevents the progression of arthritis. This procedure involves cutting the pelvis in three places (triple osteotomy) and rotating the acetabular segment (socket) to provide better coverage of the femoral head (ball portion of the hip joint). The resulting joint is stable and pain free.

In young dogs, the primary abnormality in canine hip dysplasia (see separate brochure) is joint laxity (Figures 1a and 1b). This may lead to inflammation within the joint and result in pain and lameness. The laxity in young dogs initiates a vicious cycle wherein movement and

weightbearing force the femoral head (ball portion of the hip joint) into an abnormal position. This causes interference with ossification (bone formation) of the acetabular rim (hip socket), erosion and fibrillation of the joint cartilage, stretching of the round ligament, inflammatory changes in the synovial membrane (joint lining), thickening of the joint capsule, and formation of osteophytes (bone spurs). The result is an abnormally shallow acetabulum, a flattened femoral head, and progressive arthritis.

The acute and prolonged pain and crippled movement in young dogs is the result of the sudden occurrence of microfractures (small

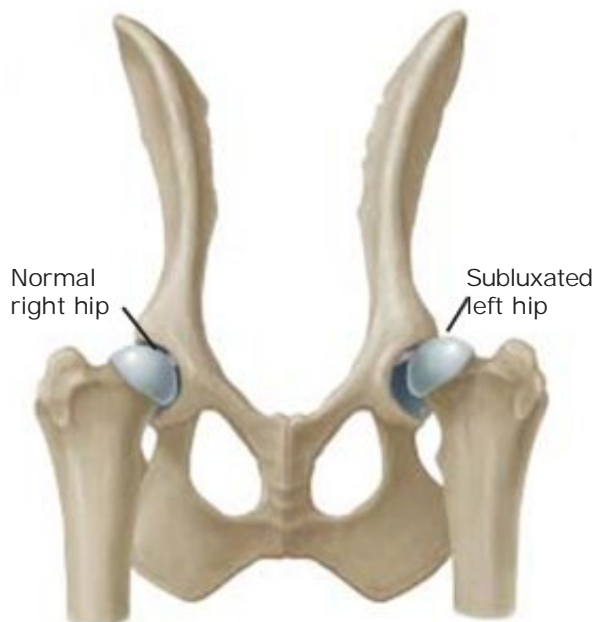
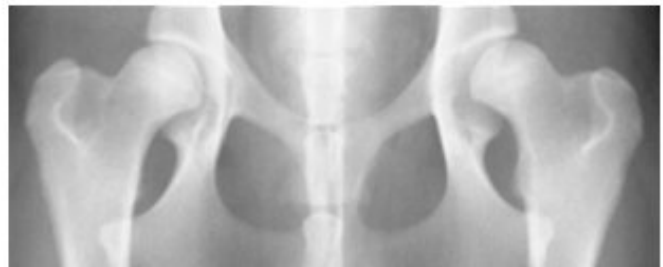

Figure 1a (left). View of normal right hip joint and abnormal left hip joint showing joint laxity (femoral head subluxation)

Figure 1b (below). X-ray view of Figure 1a: right hip is in normal position, left hip bone has slipped upward and outward (partially dislocated or subluxated)



Source of this image: Pfizer Atlas of Common Painful Conditions in Dogs and Cats, SA Johnston VMD and DN Biery, DVM, editors. Copyright 2003, Pfizer, Inc. Used with permission.



cracks or fissures) on the acetabular rim. These fractures are not visible radiographically because they are hidden behind the femoral head. They occur as a result of prolonged fatigue and bending of the immature bone of the acetabular rim while weightbearing and in motion. The changes seen in young dog's gait may include reluctance to jump, a "bunny hop" gait when running, and limping. Some dogs may cry out in pain with movement of the hip.

In young patients with minimal evidence of arthritis, a stabilizing reconstructing of the hip joint is recommended. This involves reconstructing the joint into a more normal position, allowing joint congruency, and stopping the subluxation and laxity that leads to severe arthritis. This technique is called triple pelvic osteotomy. It has been established as a reliable mode of treatment in cases which meet the case selection criteria.

Triple pelvic osteotomy is a surgical procedure which rotates the shallow acetabulum to provide improved coverage of the femoral head. By seating the hip more deeply into the socket, the primary problem of joint subluxation and the painful changes it produces are controlled.

Three to four osteotomies (bone cuts) are performed from three small incisions (Figure 2a). The socket (acetabulum) is rotated to a predetermined position which allows seating of the femoral head (Figure 2b). With the femoral head (ball) now captured in the socket, a special stainless steel plate is applied to the hip joint to maintain the new configuration.

This procedure is performed on young dogs ranging in age from four to fifteen months old, before joint subluxation has become severe or has led to arthritic changes. Radiographic examination as well as palpation are performed prior to surgery. The specific angle of acetabular rotation is established by using both radiographs and a physical examination technique called the Ortolani test. This test usually requires a mild sedative to allow for an adequate evaluation of the degree of hip laxity.

The object of triple pelvic osteotomy is to allow joint congruency between the ball (femoral head) and socket (acetabulum) so that appropriate joint development will proceed without further damage. While age of the animal is important, it is not as critical for success as the condition of the joint surfaces.

Figure 2a. Bone cuts for triple pelvic osteotomy

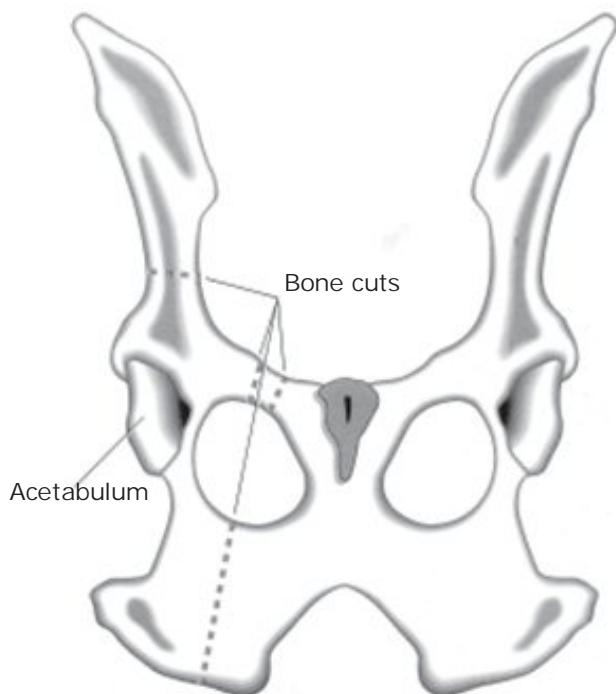
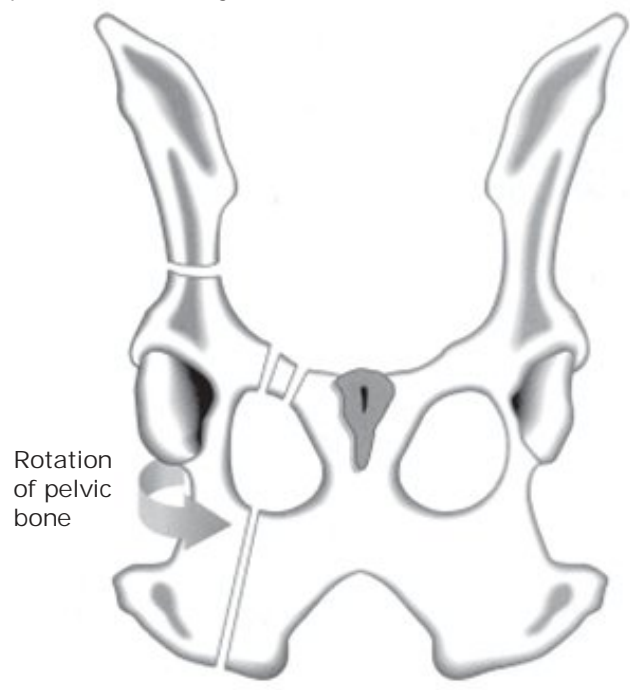


Figure 2b. Rotation of bone sections for triple pelvic osteotomy



Dogs with arthritic hips are not candidates for the triple pelvic osteotomy. However, two other procedures are available:

- Total hip replacement (see separate brochure)
- Removal of the femoral head and neck excision arthroplasty (femoral head ostectomy, FHO) (see separate brochure)

### Postoperative Care

Postoperative care is critical to long term success. The most critical element is confinement of the dog to a small area with ample bedding and good footing. Physical therapy begins at suture removal and involves flexing and extending the hip for a few minutes three or four times a day. Swimming therapy and short walks, gradually increasing in length, begin three to six weeks after surgery depending on the individual. Again, complete confinement to a small room, pen, or cage when not working on physical therapy is mandatory. Avoid slick floors, jumping, running, stair climbing, and all acrobatics until recovery is complete.

During your pet's convalescence, it may be necessary to offer assistance with ambulation (walking). Two such methods are:

#### Towel Walking

Place a sheet or large towel under your pet's abdomen as a means of support, holding an end in either hand. Use a towel or sheet that is large enough to enable you to stand in an upright position (Figure 3).

Support your pet so that he/she is unable to bear full weight on the affected limb(s). Over the passage of time (usually two to three weeks), you will notice that your pet will be able to accommodate a greater percentage of its actual weight, requiring less assistance from you.

In the case of a male dog, you will need to reposition the towel/sheet so as not to impede urinary function. This would be done once the dog is outside and ready to urinate. Allow him to lean against you while urinating. This will provide stability for him while urinating.

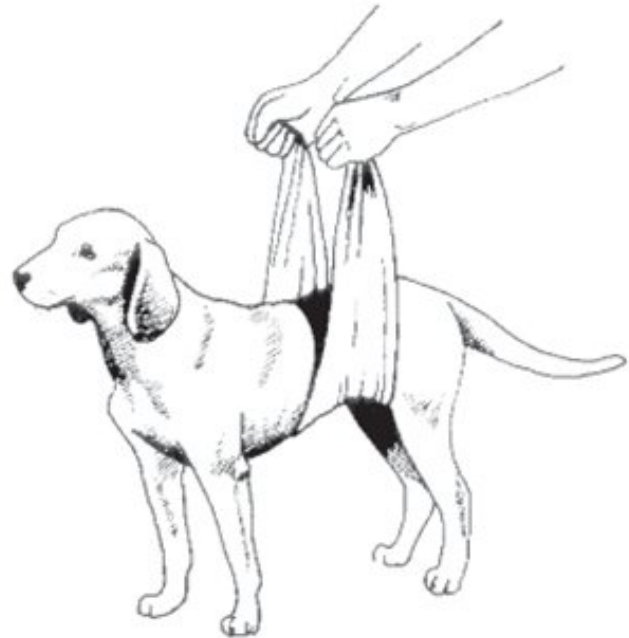


Figure 3. Supporting ambulation with a towel

#### Tail Walking

You may also assist your dog with ambulation by holding its tail in an upright manner. This serves as a 'rudder' and provides the needed stability for walking.

NOTE: Not all pets will tolerate this method. You will need to decide which method of assistance will be the most effective.

### The Use of Elizabethan Collars

Your pet is being discharged with a plastic cone-shaped collar called an Elizabethan or Buster Collar (Figure 4). This collar has been provided for use during the recuperation period and plays an important part in your pet's healing capabilities.

The collar is designed to restrict your pet's ability to reach his/her incision area or bandage(s). Licking at an incision area may result in open wounds (granulomas) that can be difficult to treat. This collar has been provided to protect these areas and also to insure that proper healing is allowed to take place.

Except as otherwise noted, all text, drawings and illustrations are copyright © Tommy L. Walker, DVM.

Figure 4. Elizabethan collar



Although your pet may exhibit some strange behavior (such as pawing at or rubbing the collar, or walking into stationary objects), after the initial placement of the collar this behavior will usually subside after approximately one to two hours time. Contrary to what one might think, it is not beneficial to remove this collar. To do so only increases the time needed to become accustomed to wearing it.

Be assured that this collar does not constrict breathing passages when worn. The animal will be able to eat, drink, sleep and eliminate while wearing this collar.

Typically, it will only remain in place for the duration of time that the surgical site is sutured or an area is to remain bandaged. We do suggest that once your pet may have this collar removed that you keep it for future use. It may prove to be quite beneficial in the future for aid

in treating minor skin irritations, "hot spots," and so forth.

## Medicating Your Dog

1. When administering medication in capsule or tablet form to your dog, you may find it much easier to simply place the medication in a small amount of food and offer it as a treat to your pet.
2. If your dog will not accept medication in the above mentioned fashion, it will be necessary for you to manually 'pill' your pet (Figure 5). Place your hand around your pet's upper jaw and gently apply pressure by pressing the lips against the teeth. Using your other hand, gently pull the lower jaw downward and place the medication in the very back of your pet's throat. By holding his/her muzzle and gently stroking the throat, you will stimulate your pet to swallow.

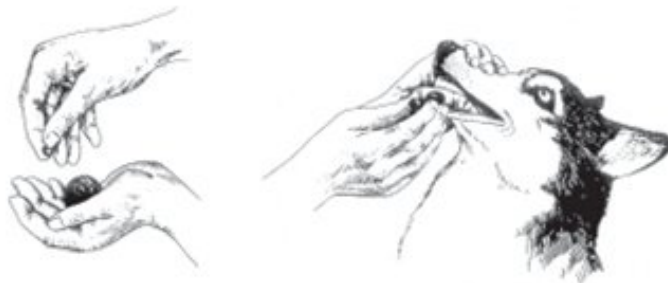


Figure 5. Administering medication to a dog

## D. C. Vets, Inc.

Tommy L. Walker, DVM, MS, Diplomate, ACVS  
website: [www.dcvets.org](http://www.dcvets.org) email: [info@dcvets.org](mailto:info@dcvets.org)  
Offices

40280 Hurley Lane, Paeonian Springs, VA 20129  
phone: 540-882-4666 fax: 540-882-4776

12106 Nebel Street, Rockville, MD 20852  
(inside Metropolitan Emergency Animal Clinic, Inc.)  
phone: 301-770-1260 fax: 301-770-1261